

VIDEOS IN CLINICAL MEDICINE

## Female Urethral Catheterization

Rafael Ortega, M.D., Linda Ng, M.D., Pavan Sekhar, B.S., and Michael Song, M.A.

### INTRODUCTION

Female urethral catheterization, the insertion of a catheter through the urethra into the urinary bladder to permit drainage of urine, is a fundamental skill for the practicing health care professional.

From the Departments of Anesthesiology and Urology, Boston University Medical Center, Boston. Address reprint requests to Dr. Ortega at the Department of Anesthesiology, Boston University Medical Center, 88 E. Newton St., Boston, MA 02118, or at [rortega@bu.edu](mailto:rortega@bu.edu).

### INDICATIONS

Female urethral catheterization is indicated for both therapeutic and diagnostic purposes. It permits effective bladder drainage in patients with acute or chronic urinary retention. A urinary catheter may be used to instill medication for local intravesical therapy or for irrigation to remove blood and clots from the urinary bladder.

N Engl J Med 2008;358:e15.

Copyright © 2008 Massachusetts Medical Society.

Urethral catheterization facilitates diagnosis in several circumstances, such as obtaining sterile urine specimens for urinalysis, measuring residual volumes after voiding, instilling contrast media for imaging procedures, and monitoring the urinary output of critically ill patients.<sup>1</sup>

### CONTRAINDICATIONS

Urethral injury can be a contraindication to catheterization. Urethral injuries are rare and most commonly result from pelvic fractures. If blood is found at the urethral meatus, urethral or bladder neck injury should be considered. If there is any question of injury, genital and rectal exams should be performed and retrograde urethrography should be considered before catheterization is attempted; consultation with a specialist before catheterization is prudent.

Since urinary catheterization can cause infection or trauma, it should not be used for routine management of urinary incontinence but should be reserved for circumstances in which noninvasive methods fail.

### EQUIPMENT

Prepackaged urethral catheterization kits are commercially available. A typical kit includes a water-absorbent underpad, a sterile fenestrated drape, sterile gloves, preparation swabs, forceps, antiseptic solution, a 10-cc syringe filled with lubricating jelly, a 10-cc syringe filled with sterile water for balloon inflation, a preconnected closed Foley system, and a specimen container. There are many types of catheters; they vary in construction material, design, and size.

### CATHETER MATERIALS

Catheters are most often made from latex. However, the use of silicone catheters is becoming more widespread as latex hypersensitivity and anaphylaxis are increasingly recognized.

Silver alloy hydrogel-coated latex catheters may decrease bacterial colonization and growth and should be considered for patients with recurrent infections.<sup>2</sup>

#### CATHETER TYPES

The Foley catheter is most frequently used in female patients requiring an indwelling catheter. It is a double-lumen, straight-tipped catheter with a balloon at its end. The balloon is inflated after insertion into the bladder to help retain the position of the catheter.

Other types of catheters include the triple-lumen catheter, which can be used for bladder irrigation, and the straight catheter, which can be used for intermittent catheterization or on a one-time basis to obtain a urine sample.

#### CATHETER SIZES

The size of the catheter is typically described in French units (circumference in millimeters). The narrowest and softest tube that can effectively be used is recommended, to limit discomfort and decrease the risk of infection.

Smaller catheters are used for narrow urethras or in patients with a history of strictures or scarring; 14-French to 16-French catheters are appropriate for most adult women. Larger catheters (18-to-24-French) may be used in patients who are at risk for obstruction of the lumen, such as patients with gross hematuria with clots.

---

#### PREPARATION

---

Explain the procedure to the patient, including possible complications. Address any specific questions or concerns.

---

#### POSITIONING

---

With the bed flat, the patient should lie supine in a lithotomy position or a frog-legged position, with legs apart and feet together.

---

#### ANATOMY

---

Begin by inspecting the genital area to identify the urethral meatus. The female urethra is a fibromuscular tube, approximately 3.5 to 4 cm long; its meatus is located below the clitoris and above the vaginal orifice.

---

#### PROCEDURE — CATHETERIZATION

---

Urethral catheterization should be performed under sterile conditions, which includes wearing sterile gloves. Inspect the sterile catheterization kit and remove it from its outer packaging. Open the inner paper wrapping to form a sterile field. To avoid contaminating the gloves, with washed hands carefully retrieve the absorbent pad from the top of the kit, and place it beneath the patient's buttocks, with the plastic side down. Then put the gloves on, and cover the patient's abdomen and superior pubic region with the fenestrated drape.

Organize the contents of the tray on the sterile field. Pour the antiseptic solution over the preparation swabs in the tray compartment. Squeeze some sterile catheter lubricant onto the tray to lubricate the catheter tip before its insertion into the urethra. After preparing the tray, using your nondominant hand, identify the urethra by spreading the labia majora and minora; place the thumb and index finger medial to the inner labia, spreading the fingers slightly and with gentle traction and pull-

ing upward toward the head of the patient (Fig. 1). This hand is no longer sterile and should not be removed from this position.

After you identify the urethral meatus, use an expanding circular motion to clean the opening with the remaining swabs. Lubricate the distal end of the catheter with the sterile jelly. Holding the catheter in the dominant hand, gently introduce the catheter tip into the meatus, and slowly advance it through the urethra into the bladder. If the catheter is accidentally contaminated, discard it and obtain a new sterile catheter before proceeding.

The female urethra is relatively short. Once you see urine flowing through the catheter, continue to advance the catheter for another 3 to 5 cm to ensure complete insertion of the balloon in the bladder (Fig. 2). You may feel resistance at the external sphincter, before the catheter is fully inserted in the bladder. Instruct the patient to breathe deeply and to relax, to facilitate passage of the catheter into the bladder.<sup>3</sup> Never force the catheter through the urethra.

Insert the catheter completely into the urethra, and do not inflate the balloon until there is return of urine, to avoid trauma due to intraurethral inflation. Inject the entire contents of the 10-cc syringe of sterile water to inflate the 5-cc balloon completely (Fig. 3). Note that the labeled volume of the balloon does not indicate the higher volume required to fill it properly; partially filled balloons may lead to catheter displacement and urethral or bladder trauma (Fig. 4). Saline should not be used because it may cause crystallization and valve malfunction.<sup>4</sup> Air also should not be used because it allows the balloon to float in the bladder, possibly creating kinks in the catheter. With the balloon completely inflated, pull gently on the catheter to fix the balloon against the bladder wall. Secure the catheter to the medial thigh of the patient with tape or a catheter-securing device. Finally, place the drainage bag in a convenient location below the level of the bladder.

---

#### COMPLICATIONS

---

The most common complications of urethral catheterization are trauma and infection. Traumatic injury may cause strictures, narrowing, and scarring of the urethra.

Infection is common in patients with indwelling catheters. Within 48 hours, up to 85% of catheters may be colonized with bacteria, which may lead to bacteriuria.

The best way to prevent complications is to avoid catheterization whenever possible. If catheterization is necessary, diligent preparation, meticulous attention to proper sterile technique, removal of the catheter as early as clinically possible, and vigilance are mandatory.

---

#### TROUBLESHOOTING — DIFFICULT CATHETERIZATIONS

---

In some patients, the urethra may be difficult to catheterize for various reasons, including previous operative procedures, obesity, and anatomical variants of pelvic organs. If you are unable to pass the catheter through the urethra or if you encounter resistance, there may be a kink in the urethra because of pelvic organ prolapse. It may be necessary to reduce the prolapse by gently applying pressure to it and guiding the prolapsed tissue back into the vagina.

If the urethra is not easily visualized, place the index finger of your nonsterile hand inside the vaginal orifice and gently apply pressure upward, both to straighten the urethra and to allow the finger to guide the catheter into the urethral opening (Fig. 5). If you feel the catheter beside the finger, it is incorrectly placed inside the vagina. In this case the catheter should be removed and a new sterile catheter used to attempt catheterization again. In morbidly obese patients, an assistant is often necessary to aid in retraction.



Figure 1. Identifying the Urethra.

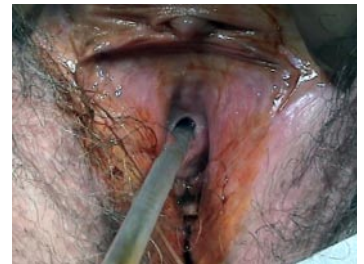

Figure 2. Advancing the Catheter.

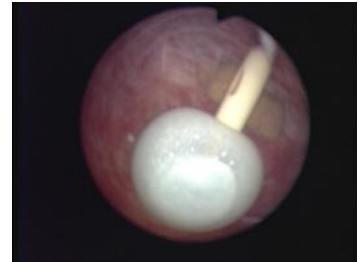


Figure 3. Inflated Balloon.

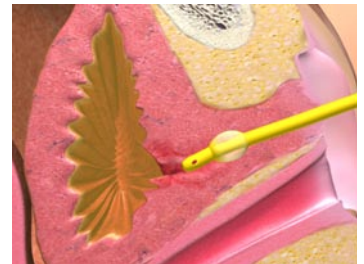

Figure 4. Partially Inflated Balloon in Urethra.

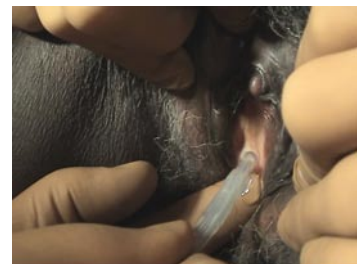

Figure 5. Guiding the Catheter.

## REFERENCES

1. Cravens DD, Zweig S. Urinary catheter management. *Am Fam Physician* 2000; 61:369-76.
2. Rupp ME, Fitzgerald T, Marion N, et al. Effect of silver-coated urinary catheters: efficacy, cost-effectiveness, and antimicrobial resistance. *Am J Infect Control* 2004;32:445-50.
3. Tanabe P, Steinmann R, Anderson J, Johnson D, Metcalf S, Ring-Hurn E. Factors affecting pain scores during female urethral catheterization. *Acad Emerg Med* 2004;11:699-702.
4. Daneshmand S, Youssefzadeh D, Skinner EC. Review of techniques to remove a Foley catheter when the balloon does not deflate. *Urology* 2002;59:127-9.

Copyright © 2008 Massachusetts Medical Society.

If the flow of urine is slow or nonexistent, the catheter may be obstructed or in the wrong site, or the bladder may be empty. Flush the catheter with saline. If saline or urine freely returns, the catheter is properly inserted.

## SUMMARY

Female urethral catheterization performed appropriately is an invaluable procedure for both therapeutic and diagnostic purposes. Mastering the proper insertion technique and understanding the risks and benefits of the procedure behooves all practicing health professionals.